

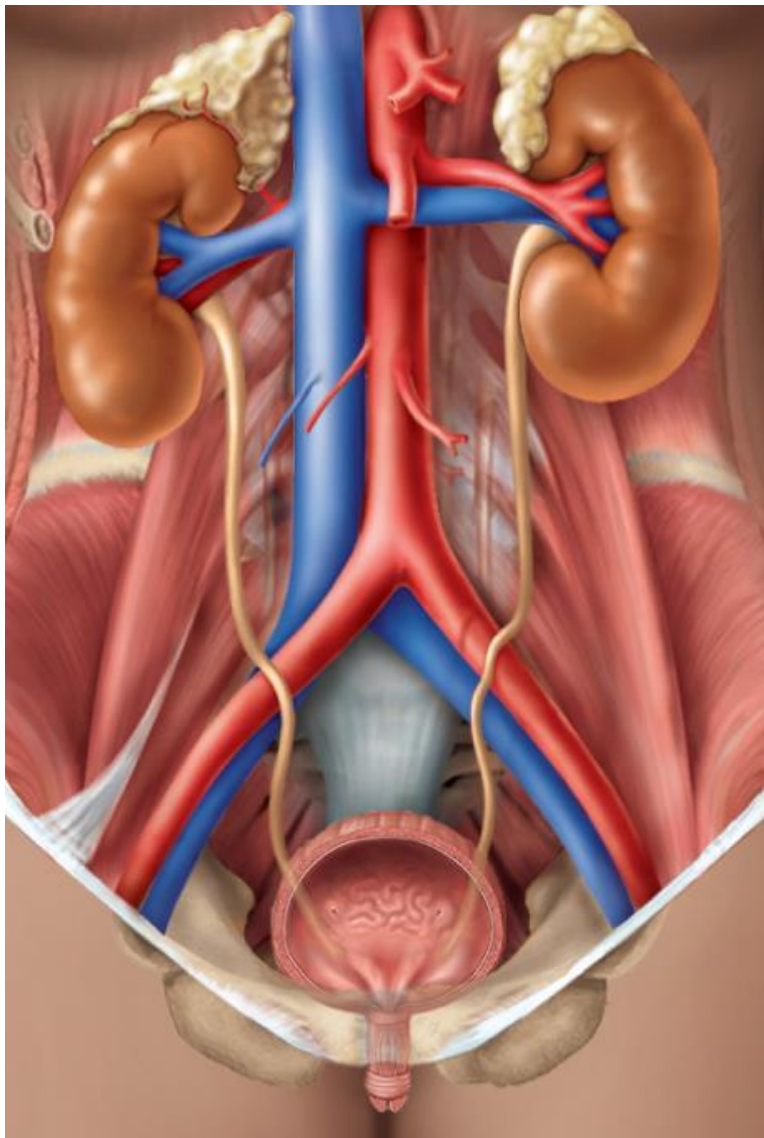
Urinary Lab

In this lab students will learn to identify structures of the urinary system. Use your textbook to identify and label the structures of the urinary system listed below. Watch the video that is associated with this lab. ***Only the terms provided in the lab PDF will receive credit on lab quizzes and exams.**

Activity One: Urinary System

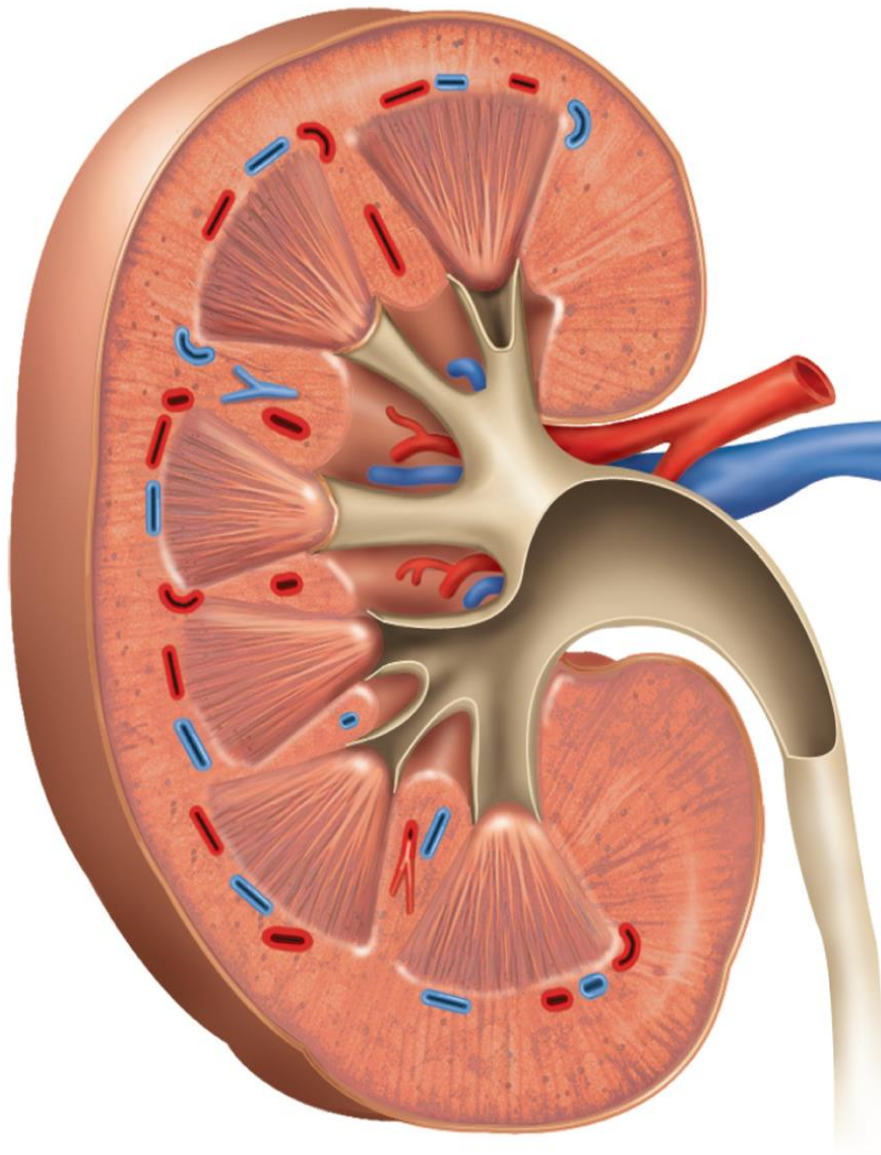
Please identify and label the following urinary structures listed below. Use your textbook to complete this activity.

- | | |
|--|--|
| <input type="checkbox"/> Right adrenal gland (not part of this system) | <input type="checkbox"/> Left renal artery |
| <input type="checkbox"/> Left adrenal gland (not part of this system) | <input type="checkbox"/> Right renal vein |
| <input type="checkbox"/> Right kidney | <input type="checkbox"/> Left renal vein |
| <input type="checkbox"/> Left kidney | <input type="checkbox"/> Right ureter |
| <input type="checkbox"/> Right renal artery | <input type="checkbox"/> Left ureter |
| | <input type="checkbox"/> Urinary bladder |



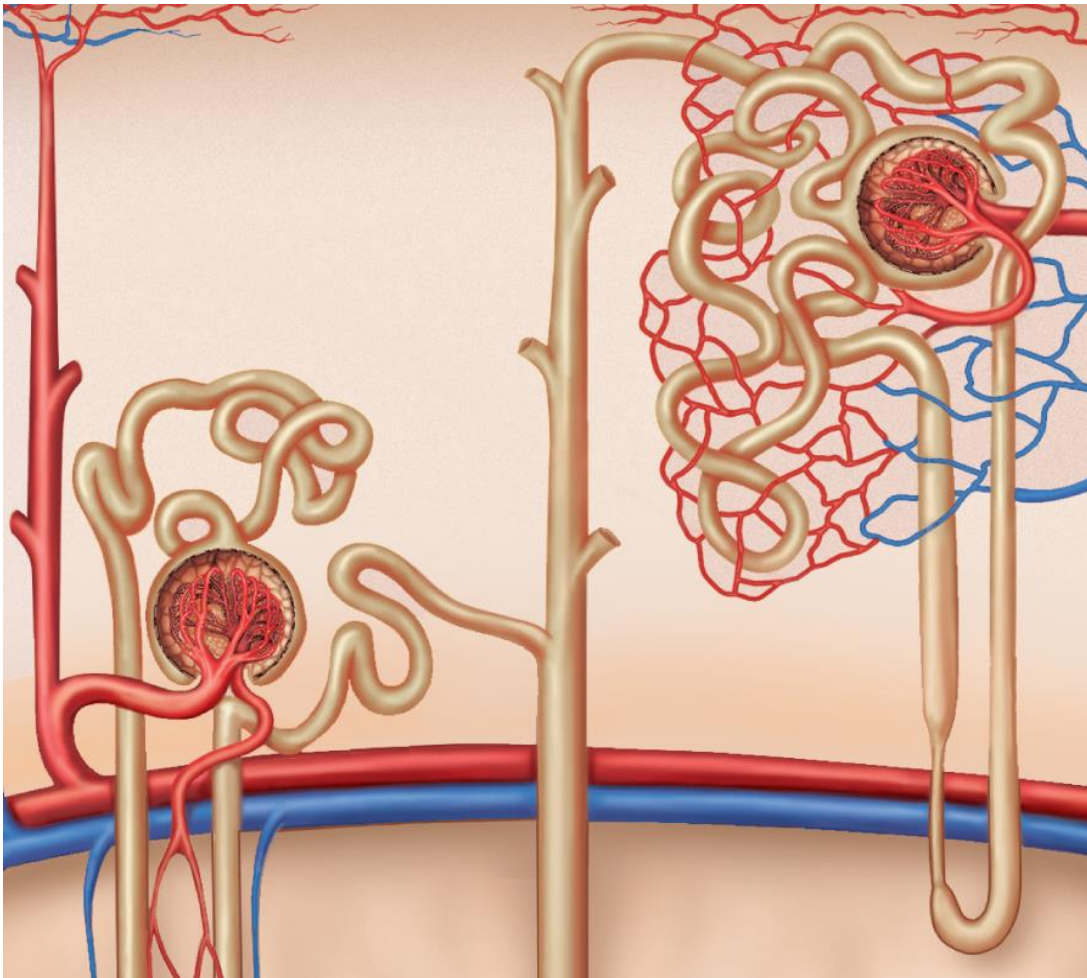
KIDNEY

- Renal artery
- Renal vein
- Fibrous capsule
- Renal cortex
 - Renal column
- Renal medulla
 - Renal pyramid
- Minor calyx
- Major calyx
- Renal pelvis
- Ureter



NEPHRON

- __ Afferent arteriole
- __ Efferent arteriole
- __ Glomerulus
- __ Glomerular capsule
- __ Proximal convoluted tubule
- __ Nephron loop
 - __ Descending limb
 - __ Ascending limb
- __ Distal convoluted tubule
- __ Collecting duct
- __ Peritubular capillaries



Activity Two: Urinary System (Model)

Please identify and label the following structures of the urinary system (same as above) on the models below. Watch the Urinary Lab Video to help you complete this activity.

URINARY SYSTEM

- Right adrenal gland (not part of this system)
- Left adrenal gland (not part of this system)
- Right kidney
- Left kidney
- Right renal artery
- Left renal artery
- Right renal vein
- Left renal vein
- Right ureter
- Left ureter
- Urinary bladder

KIDNEY

- Renal artery
- Renal vein
- Fibrous capsule
- Renal cortex
 - Renal column
- Renal medulla
 - Renal pyramid
- Minor calyx
- Major calyx
- Renal pelvis
- Ureter

NEPHRON

- Afferent arteriole
- Efferent arteriole
- Glomerulus
- Glomerular capsule
- Proximal convoluted tubule
- Nephron loop
 - Descending limb
 - Ascending limb
- Distal convoluted tubule
- Collecting duct
- Peritubular capillaries

