



ST. CATHERINE  
UNIVERSITY

# Male Reproductive System

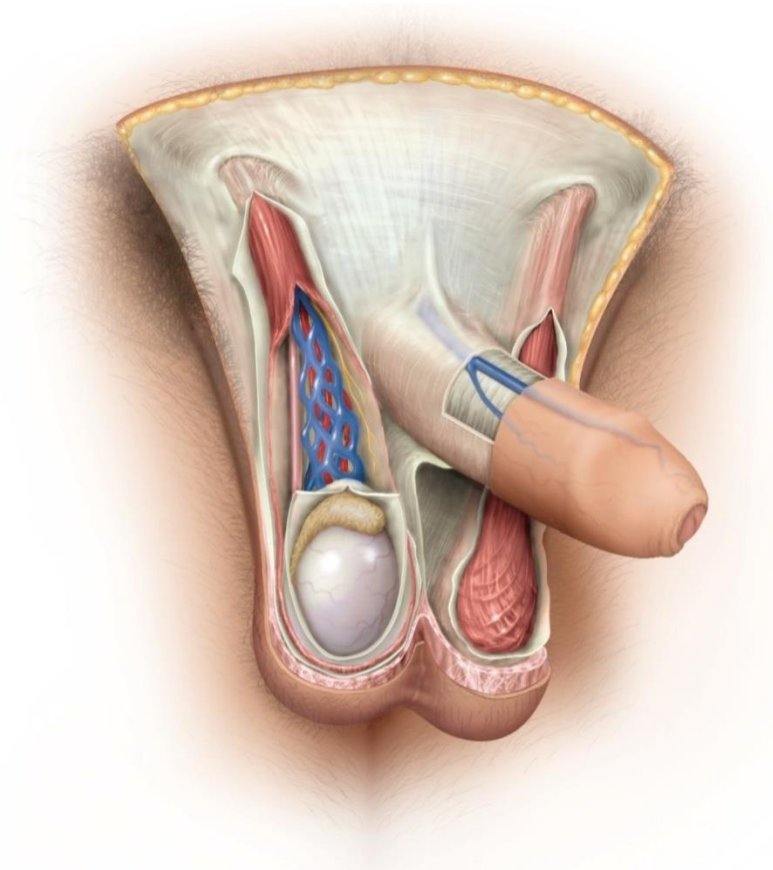
# Male Reproductive Functions



- Sperm Production
- Produce sex hormones

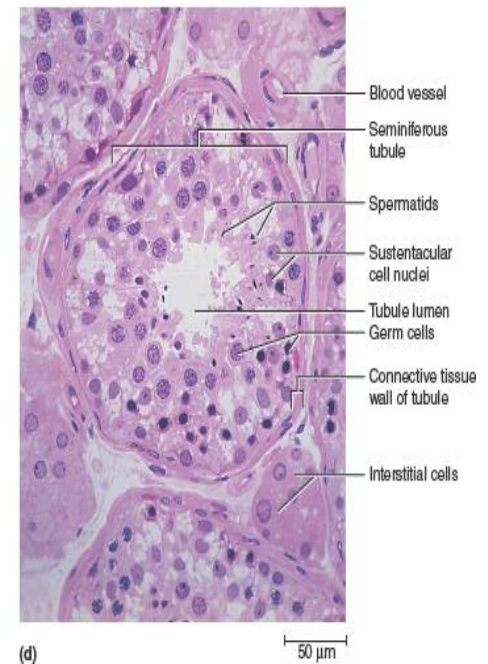
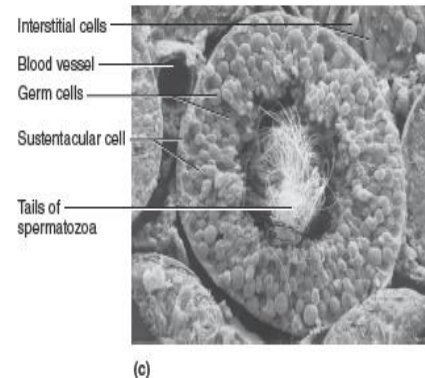
# Genitalia

- Scrotum
  - Testes
  - Spermatic cord
  - Dartos muscle
  - Cremaster muscle



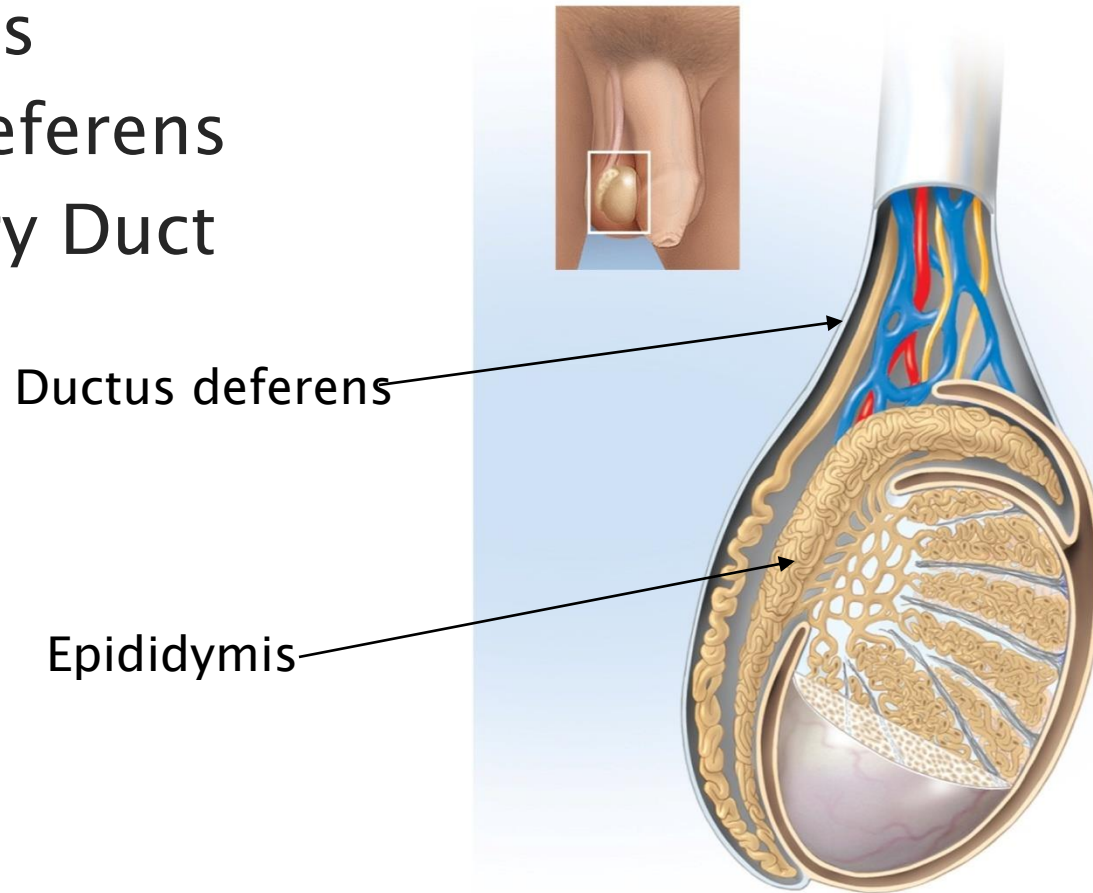
# Genitalia Cont'd

- Testes
  - Seminiferous Tubules
  - Germinal epithelium
  - Sustentacular cells
  - Interstitial Cells
  - Rete Testis



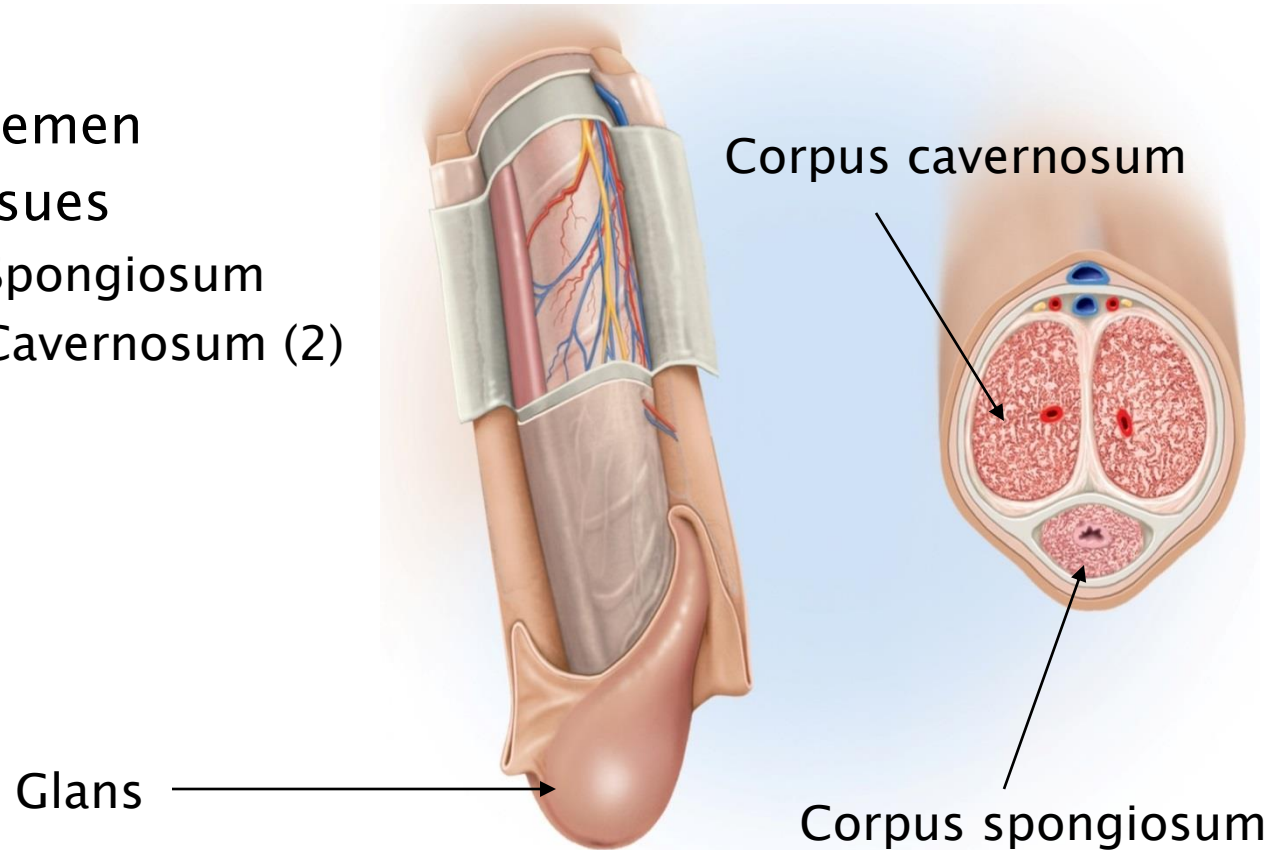
# Spermatic Ducts

- Epididymis
- Ductus Deferens
- Ejaculatory Duct



# Genitalia

- Penis
  - Transfers semen
  - Erectile Tissues
    - Corpus Spongiosum
    - Corpus Cavernosum (2)
  - Glans



# Spermatogenesis

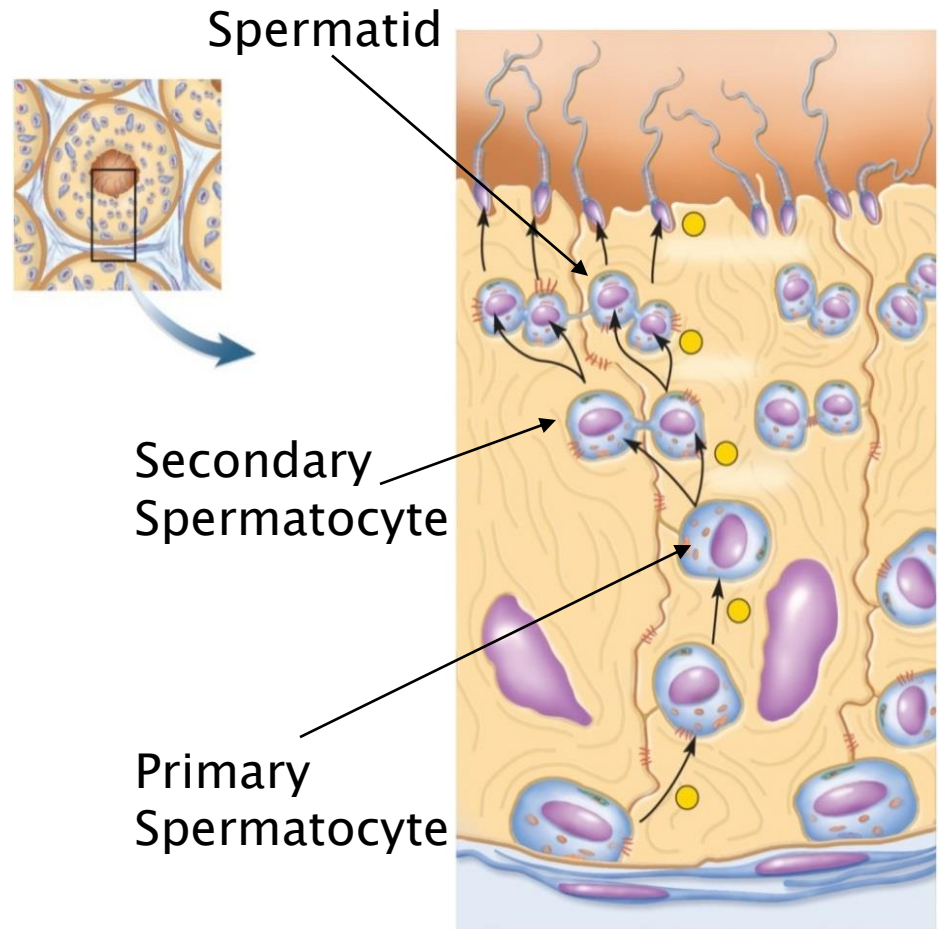
Primordial germ cells

Spermatogonia

Primary spermatocytes

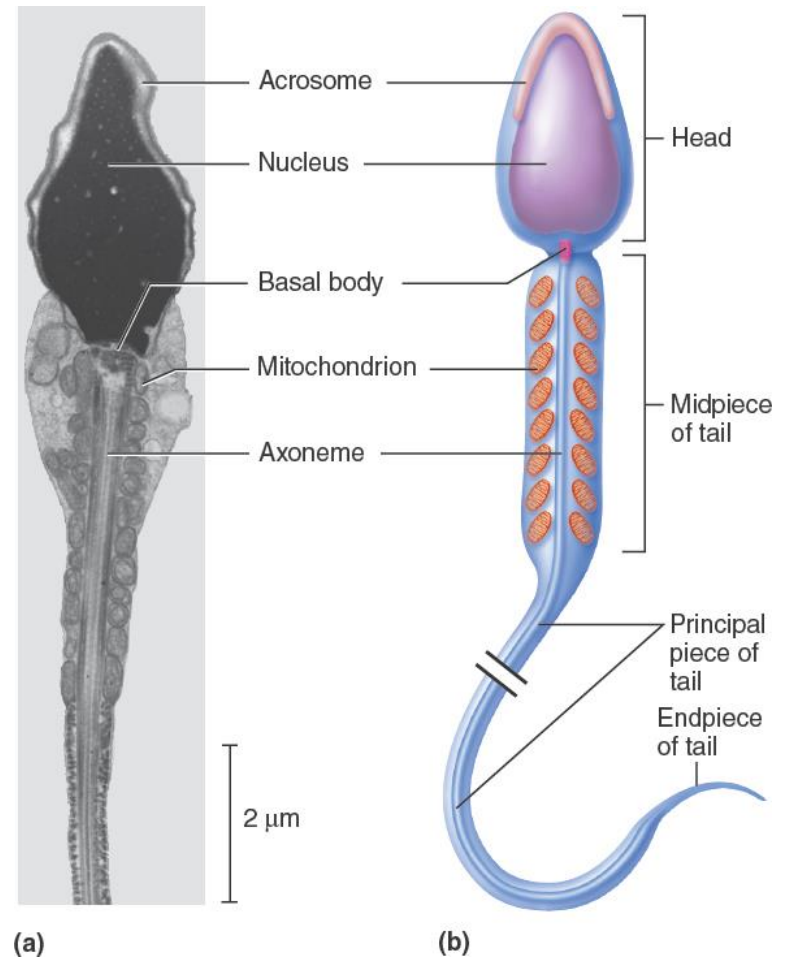
Secondary spermatocytes

Spermatids



# Sperm Cells

- Head
- Midpiece
- Tail





# Semen

- Fluid expelled ejaculation
- Seminal fluid
- Prostate fluid
- Bulbourethral fluid